The Nerve
eISSN2465-891X The Nerve.2017.3(2):81-84
https://doi.org/10.21129/nerve.2017.3.2.81
CASE REPORT
www.thenerve.net

Penetrating Brain Injury Caused by a Nail Gun

Sung Hoon Min, Chang-young Kweon, Wooram Shin

Department of Neurosurgery, Presbyterian Medical Center, Jeonju, Republic of Korea

Corresponding author: **Wooram Shin**
Department of Neurosurgery, Presbyterian Medical Center, 365, Seowon-ro, Wansan-gu, Jeonju 54987, Republic of Korea
Tel: +82-63-230-1420
Fax: +82-63-230-1426
E-mail: hisarang@daum.net

Received: August 2, 2017
Revised: August 8, 2017
Accepted: August 10, 2017

Nail guns are used as a tool to drive a nail into hard materials with ease. Head injuries caused by nail guns are extremely rare; most cases have good clinical outcomes, while some are life-threatening. Catastrophic outcomes in penetrating nail-gun injuries caused by high-velocity devices are associated with deep brain damage, vascular injury, and delayed vascular disease causing intracranial hemorrhage. We present herein an unusual case of penetrating intracranial nail gun injury.

Key Words: Craniocerebral trauma; Head injuries; Penetrating; Suicide; Attempted

INTRODUCTION

The nail gun is a tool to drive a nail into hard materials with ease. Nail guns fall into 2 types: air-powered and explosive-powered types. The air-powered type is powered by compressed air, and the explosive-powered type uses gas pressure acting directly on the nail to drive it[6]. In spite of the convenience of nail guns, nail gun injuries can occur when a nail gun is used carelessly or misused, such as in a suicide attempt. Head injuries caused by nail guns are extremely rare; most cases have good clinical outcomes, while some are life-threatening[10].

In this paper, an unusual case of penetrating intracranial nail gun injury is presented.

CASE REPORT

A 53-year-old man presented to our Emergency Department with a 1-hr history of unconsciousness after nail gun injury. He committed suicide by shooting a nail gun in his forehead. At presentation, his Glasgow Coma Scale (GCS) score was 13 points (eye opening 3 points, verbal response 4 points, and motor response 6 points). The pupil size was 2 mm, and the pupil reflex was present on both sides. The muscle strength of extremities was normal. There was an entrance wound in the right forehead, but no nail was found. There was no specific medical or family history. Initial skull X-ray revealed the presence of a nail in the cranial cavity (Fig. 1). A brain computed tomography (CT) scan demonstrated a comminuted and depressed fracture of the frontal bone, right frontal lobe contusion with hematoma, and intraventricular hemorrhage (IVH) (Fig. 2A). The brain CT scan also revealed the nail directing toward the entrance and a hematoma in the path of the projectile (Fig. 2B). Brain CT angiography could not be performed because the patient was irritable. At presentation, white blood cell count was 16,400/μL, erythrocyte sedimentation rate was 33 mm/hr, and C-reactive protein was 1.12 mg/L. Bilateral frontal craniotomy was performed via the bicoronal approach. Some bony fragments scattered along the path of the nail were removed, and a large amount of hematoma was sucked out. Since there was no injury to vessels, the nail that lodged in the right front horn of the lateral ventricle was taken out carefully. The nail measured 3 cm (Fig. 3). The tissue surrounding the nail was cultured for fungi and bacteria. A drain catheter was inserted into the intraventricular cavity. The bone flap was secured with 2 craniofix devices and 1 burr hole-type mesh.

A postoperative brain CT scan exhibited the remnant of IVH

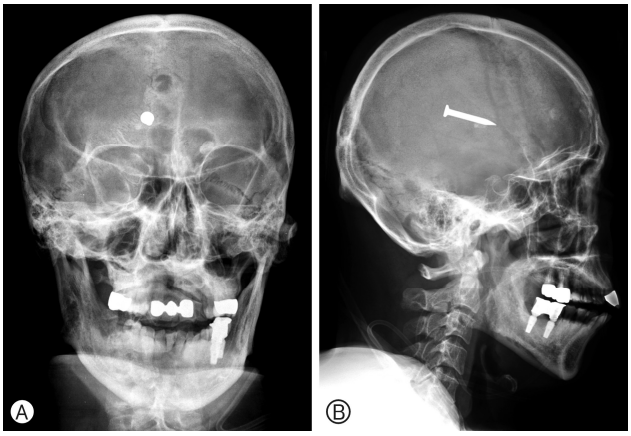

Fig. 1. Initial (A) anteroposterior view and (B) lateral view of skull X-ray reveal the presence of a nail in the cranial cavity.

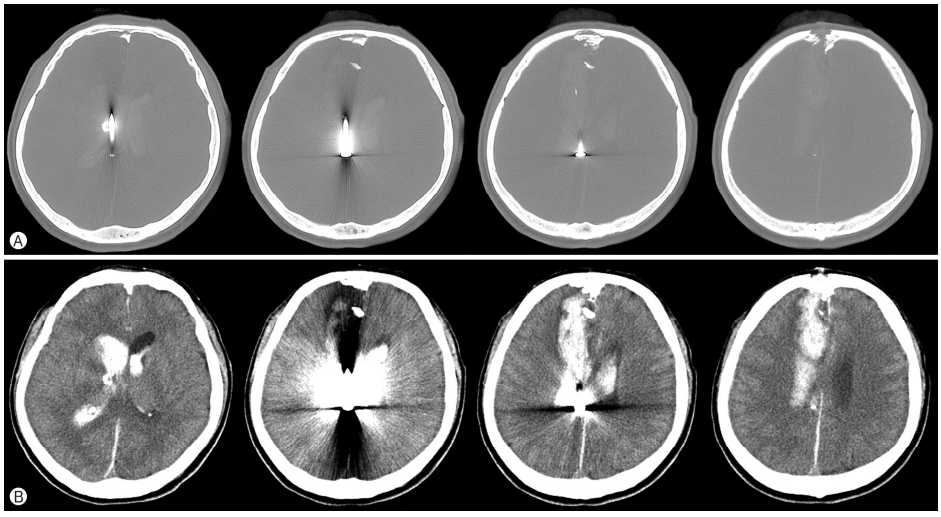

Fig. 2. (A) Preoperative brain computed tomography (CT) scan with bone window reveals a comminuted and depressed fracture of the frontal bone and a nail directing toward the entrance. (B) Preoperative brain CT scan reveals both lateral ventricle containing intraventricular hemorrhage and hemorrhage in the path of the projected nail.



Fig. 3. The penetrating nail measuring 3 cm.

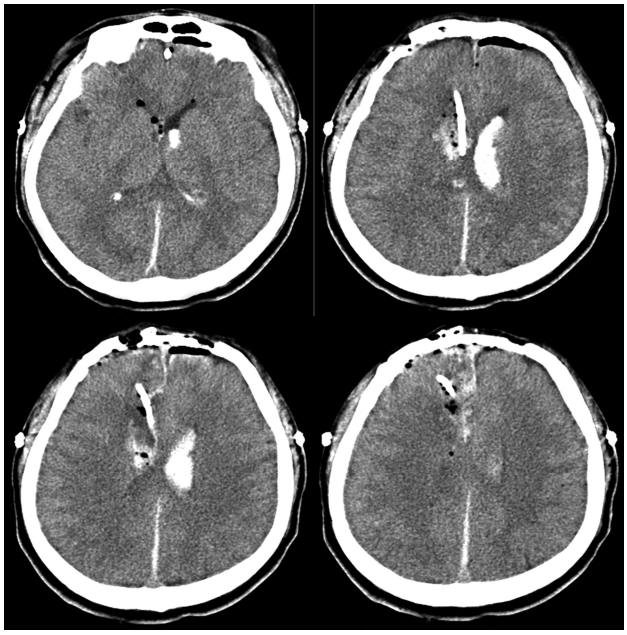

Fig. 4. A postoperative brain computed tomography scan shows the remnant of intraventricular hemorrhage and no bone fragment.

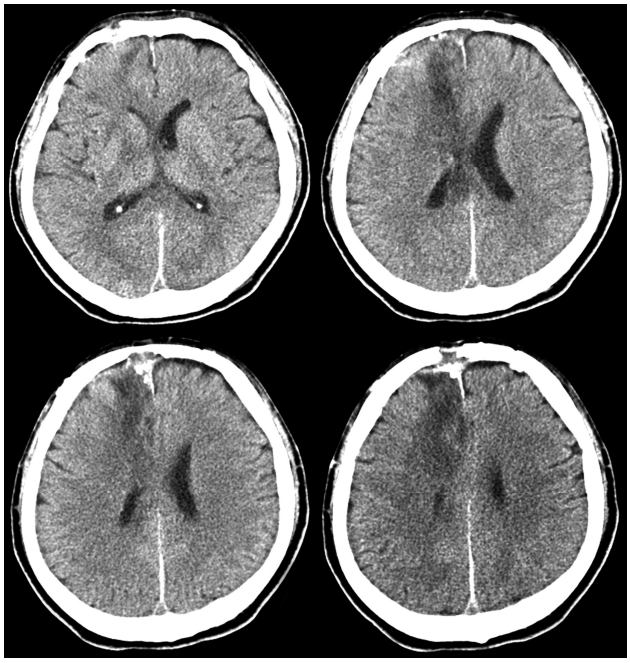

Fig. 5. A brain computed tomography scan taken 14 days after trauma shows the completely absorbed intraventricular hemorrhage and a low-density lesion in the path of the projected nail.

but no bony fragment (Fig. 4). The patient was treated in the neurointensive care unit. Anticonvulsants and third-generation cephalosporins were prophylactically administered. He had no fever, and his vital signs were stable. He had alert metal status and no motor weakness. Cranial function test results were all normal. Since the patient still had suicidal ideation, depressed mood, and anxiety, he was referred to the Depart-

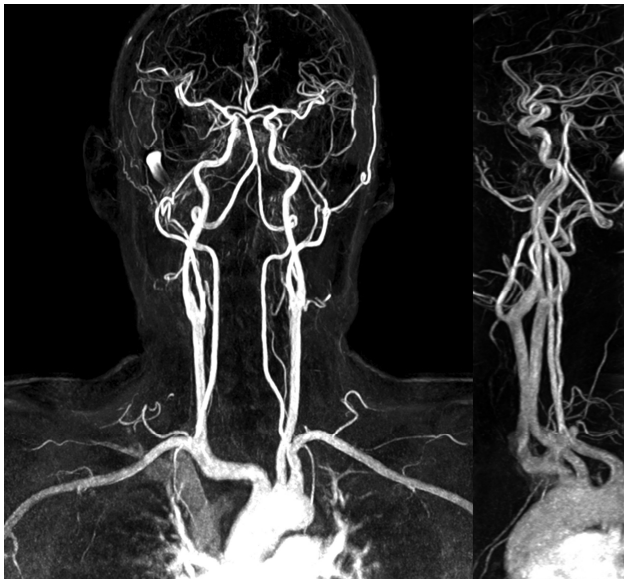

Fig. 6. A brain magnetic resonance angiogram taken 1 month after trauma shows intact anterior and posterior circulation on both sides without any vascular abnormalities such as pseudoaneurysm.

ment of Psychiatry for further evaluation. Cultures of the tissue surrounding the nail, cerebrospinal fluid, and blood were all negative. A brain CT scan taken 14 days after surgery showed the completely absorbed remnant of IVH and no abnormal finding except a low-density lesion along the path of the nail (Fig. 5). A brain magnetic resonance angiogram taken 1 month after surgery revealed intact anterior and posterior circulation on both sides without any vascular abnormalities such as pseudoaneurysm (Fig. 6).

DISCUSSION

Historically, intracranial nail gun injury has been associated with favorable outcomes[10]. Litvack et al.[4] reported a 33-year-old man who had 12 nail gun nails impacted in both temporal areas and only showed slight limitation of mandibular movement, mild paralysis of the right face, dysarthria, and short-term memory impairment. Selvanathan et al.[9] reported a case of a 52-year-old patient who only presented with visual impairment due to the presence of 7 nail-gun nails that lodged in both frontal areas. The mild clinical manifestation of these cases may have been attributed to the low velocity of the nail guns.

The force of the projectile is proportional to its velocity. It can damage adjacent structures in the path of the projectile and can introduce bony fragments that are capable of causing brain damage[5,10]. There have been a few reports of catastrophic outcomes following nail gun injury. Oh et al.[7] reported a case of a patient with nail gun injury who remained in a state of stupor even after surgical treatment. Rezai et al.[8] reported 1 patient who developed a left posterior cerebral artery pseudoaneurysm with associated intraventricular and subarachnoid hemorrhage. Penetrating trauma to the cerebrovascular system can cause arterial dissection, traumatic aneurysm, arterial or venous rupture/thrombosis, and arteriovenous fistula. Furthermore, this trauma can also cause life-threatening intracranial hemorrhage (ICH)[1,3]. Life-threatening vascular abnormalities, such as pseudoaneurysm with potential ICH, occur in 25% of patients with penetrating nail-gun injuries[10]. Delayed pseudoaneurysm occurs within 3 to 4 weeks after trauma and carries a mortality rate of 50%[2,4]. Therefore, it is mandatory to perform angiography 3 to 4 weeks after trauma in order to confirm vascular pathology.

CONCLUSION

We reported the case of a penetrating brain injury caused by a nail gun. Head injuries caused by nail guns are extremely rare; most cases have good clinical outcomes, while some are life-threatening. Catastrophic outcomes in penetrating nail-gun injuries caused by high-velocity devices are associated with deep brain damage, vascular injury, and delayed vascular disease causing ICH. Therefore, it is mandatory to perform angiography 3 to 4 weeks after trauma in order to confirm vascular pathology. We don't know how to spin the nail in the brain.

CONFLICTS OF INTEREST

No potential conflict of interest relevant to this article was reported.

REFERENCES

1. Amirjamshidi A, Rahmat H, Abbassioun K: Traumatic aneurysms and arteriovenous fistulas of intracranial vessels associated with penetrating head injuries occurring during war: principles and pitfalls in diagnosis and management. A survey of 31 cases and review of the literature. J Neurosurg 84:769-780, 1996
2. Blankenship BA, Baxter AB, McKahn GM, 2nd: Delayed cerebral artery pseudoaneurysm after nail gun injury. AJR Am J Roentgenol 172:541-542, 1999
3. Guyot LL, Kazmierczak CD, Diaz FG: Vascular injury in neurotrauma. Neurol Res 23:291-296, 2001
4. Litvack ZN, Hunt MA, Weinstein JS, West GA: Self-inflicted nail-gun injury with 12 cranial penetrations and associated cerebral trauma. Case report and review of the literature. J Neurosurg 104:828-834, 2006
5. Luo W, Liu H, Hao S, Zhang Y, Li J, Liu B: Penetrating brain injury caused by nail guns: two case reports and a review of the literature. Brain Inj 26:1756-1762, 2012
6. Nagib MG, Rockswold GL, Sherman RS, Lagaard MW: Civilian gunshot wounds to the brain: prognosis and management. Neurosurgery 18:533-537, 1986

7. Oh HH, Kim Y, Park SC, Ha YS, Lee KC: Nail gun induced open head injury: a case report. Korean J Neurotrauma 10:139-141, 2014
8. Rezai AR, Lee M, Kite C, Smyth D, Jafar JJ: Traumatic posterior cerebral artery aneurysm secondary to an intracranial nail: case report. Surg Neurol 42:312-315, 1994
9. Selvanathan S, Goldschlager T, McMillen J, Campbell S: Penetrating craniocerebral injuries from nail-gun use. J Clin Neurosci 14:678-683, 2007
10. Woodall MN, Alleyne CH, Jr.: Nail-gun head trauma: A comprehensive review of the literature. J Trauma Acute Care Surg 73:993-996, 2012